



Total Abdominal Hysterectomy (TAH) and anatomy review

Courtesy of:

Dr. Karen Meyer (GYN)
Good Samaritan Hospital Advocate
Downers Grove, IL
10 January 2008

Photos: David Sash

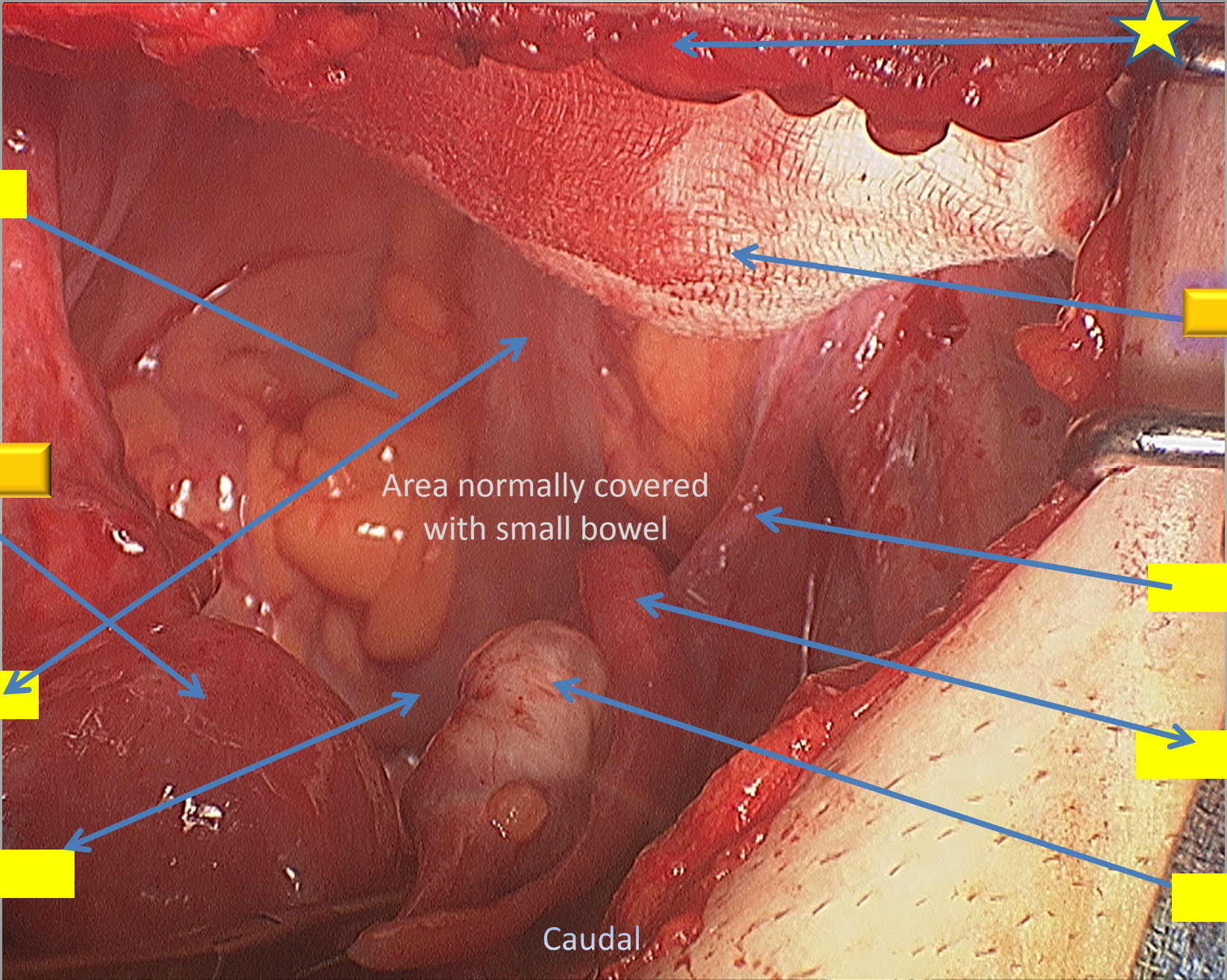




Test your anatomy knowledge

Click on next slide

Anterior Abdominal Wall



Area normally covered with small bowel

Caudal

Anterior Abdominal Wall

Small bowel behind DASH

Peri Rectal Fat

DASH Size 2

UTERUS

Area normally covered with small bowel

Infundibulo pelvic ligament

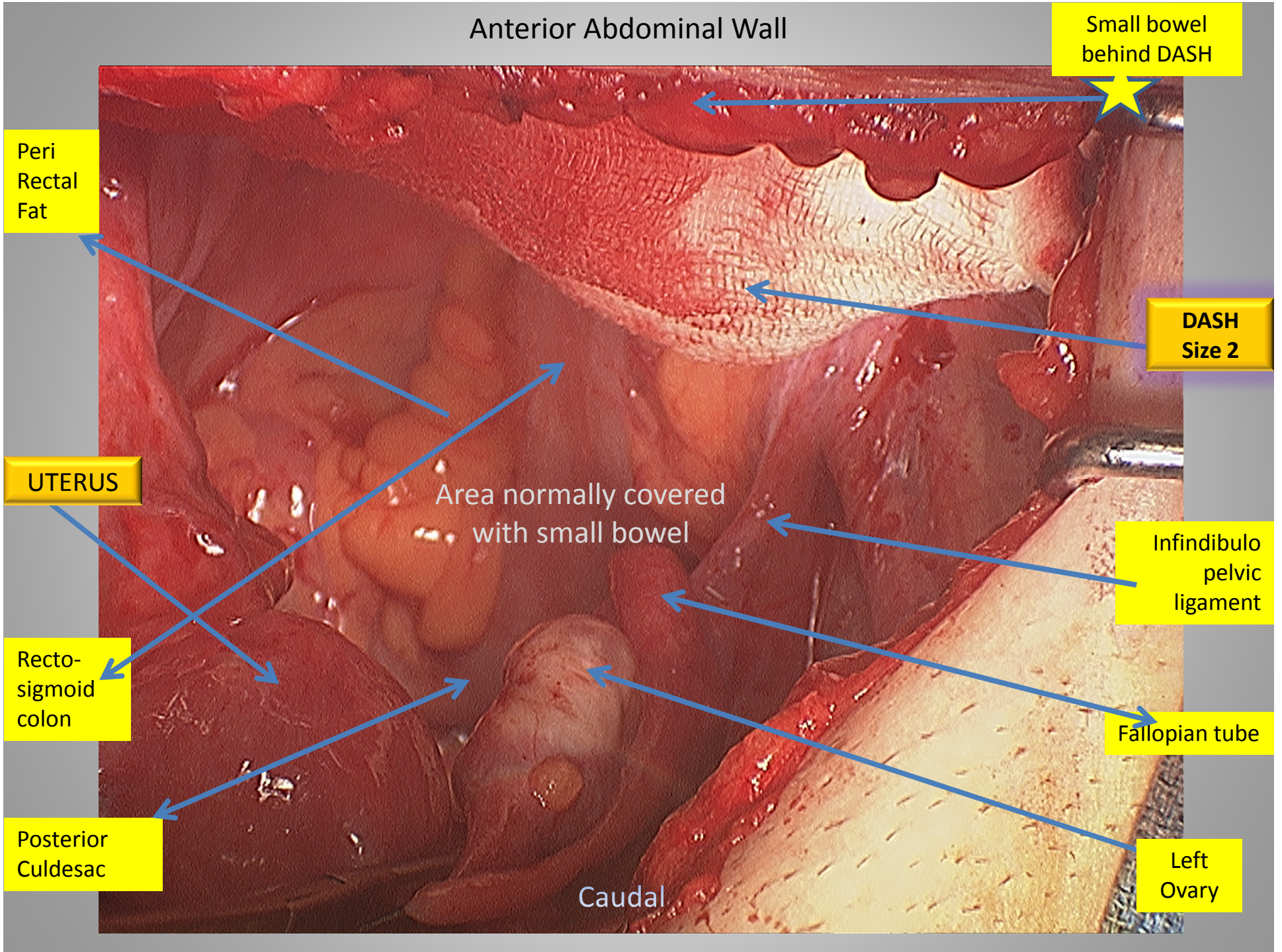
Recto-sigmoid colon

Fallopian tube

Posterior Culdesac

Left Ovary

Caudal



DASH (size 2) Orientation in this case

